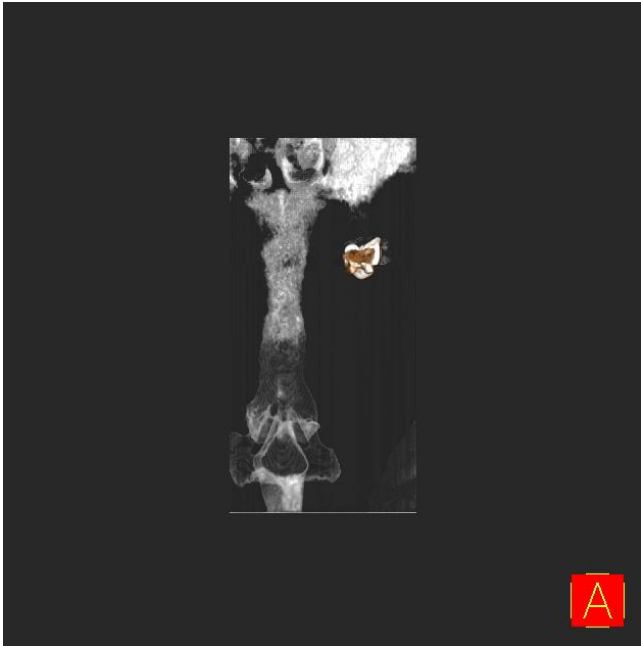




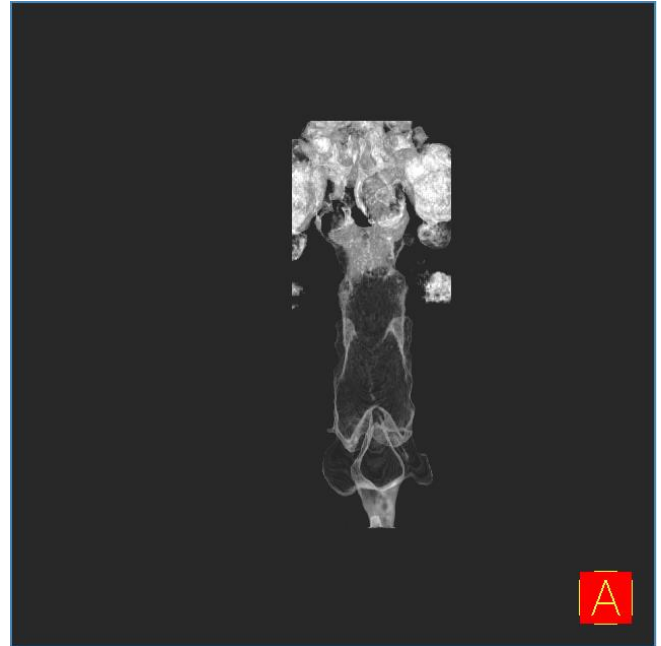
Maric, Ivan

AHI PräOP: 17,2/h am 20.02.16 | AHI PostOP: 1,7/h am 12.02.18

Atemwege transversale Ebene

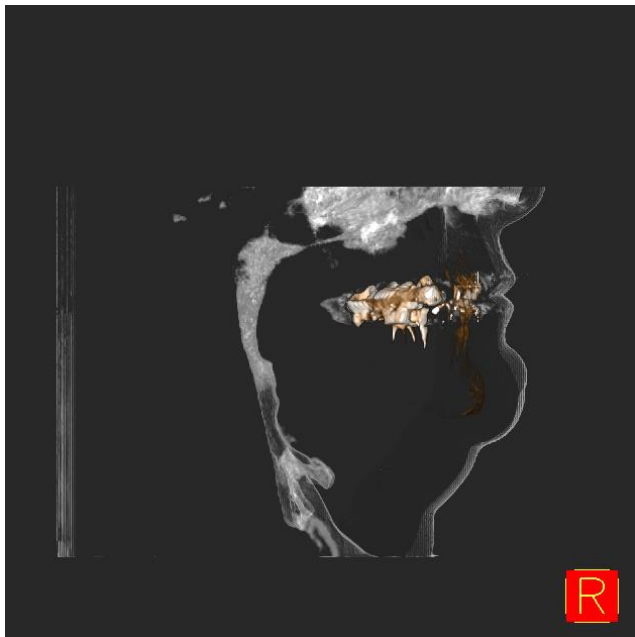


Vorher

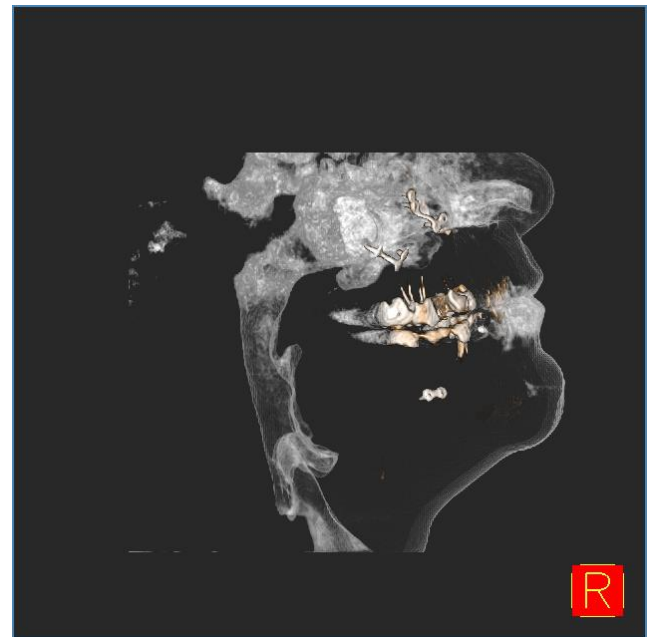


Nachher

Atemwege sagittale Ebene



Vorher



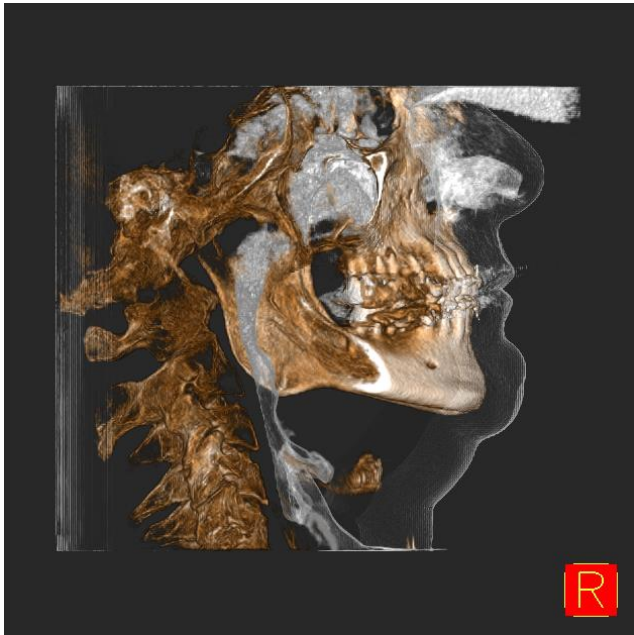
Nachher



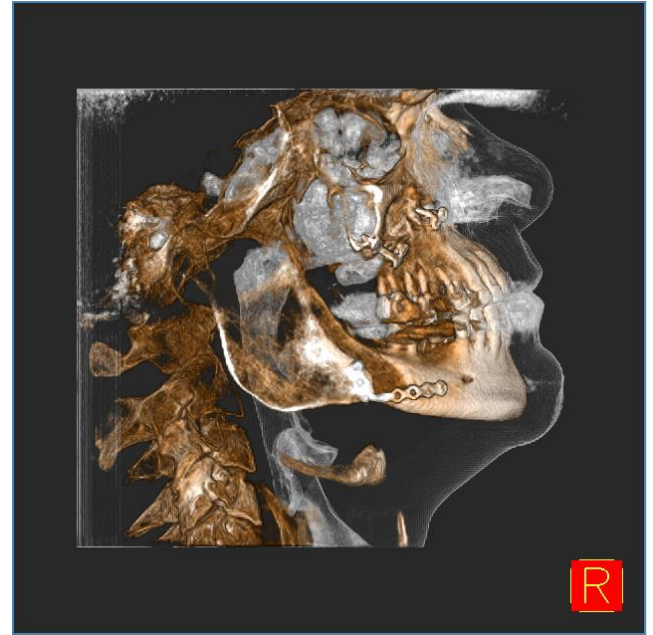
Maric, Ivan

AHI PräOP: 17,2/h am 20.02.16 | **AHI PostOP:** 1,7/h am 12.02.18

Rotation der Kiefer

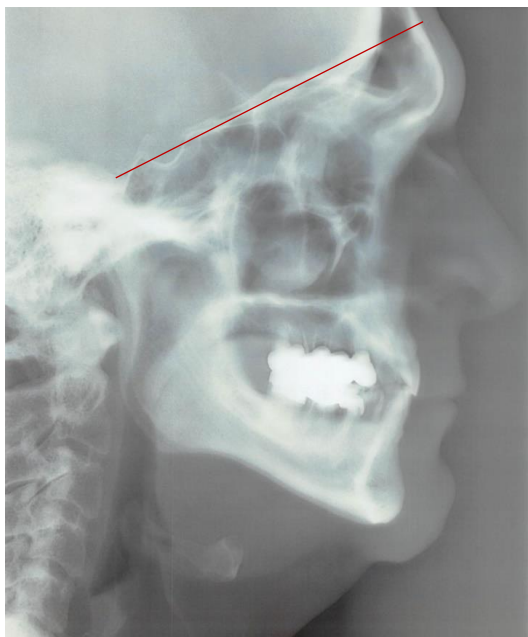


Vorher

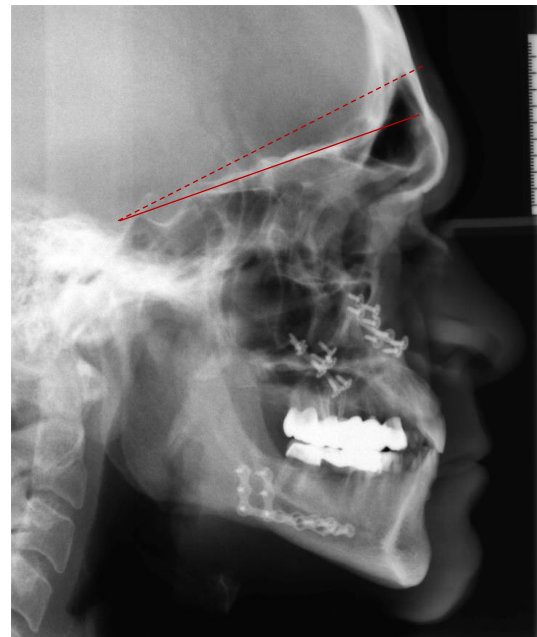


Nachher

Haltungsänderung Kopfneigung zu Halswirbelsäule



Vorher



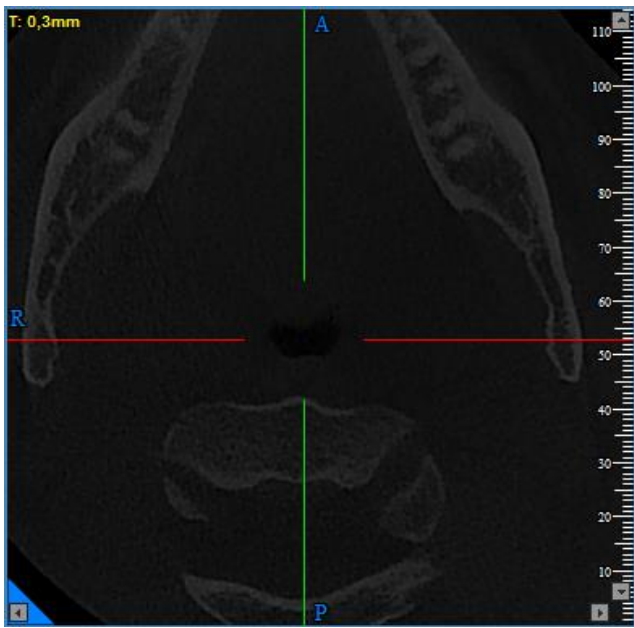
Nachher



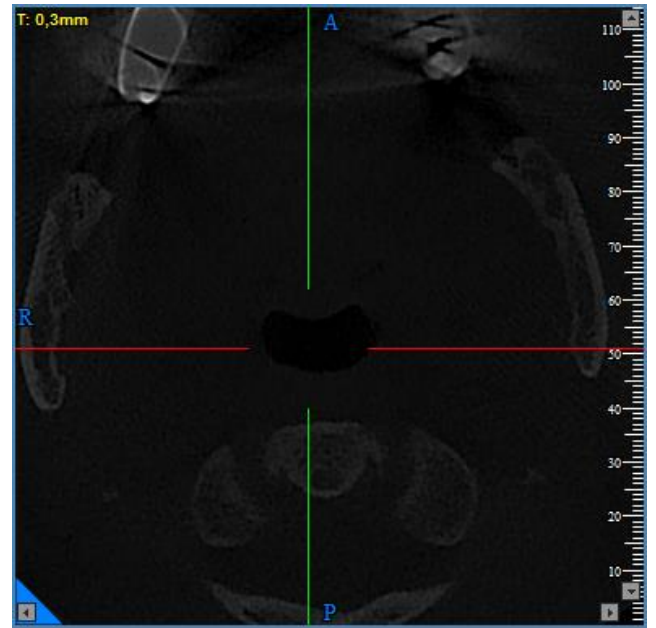
Maric, Ivan

AHI PräOP: 17,2/h am 20.02.16 | AHI PostOP: 1,7/h am 12.02.18

Engste Stelle Axial

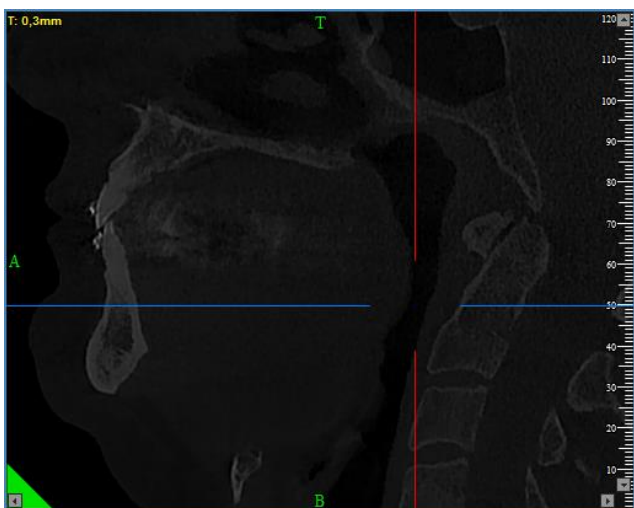


Vorher

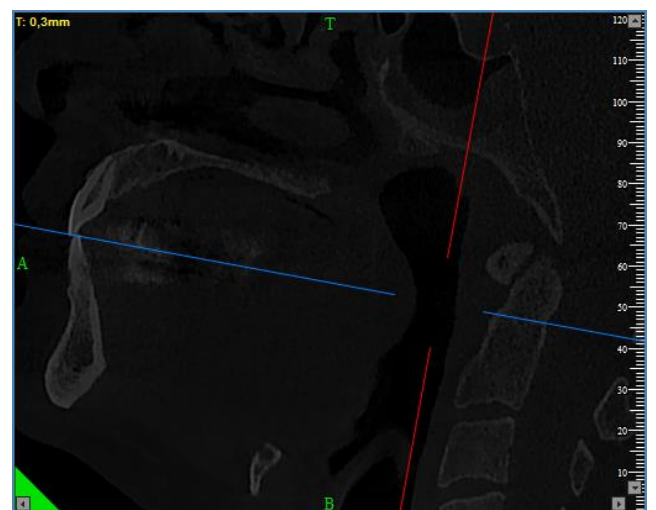

Nachher

Engste Stelle Sagittal



Vorher



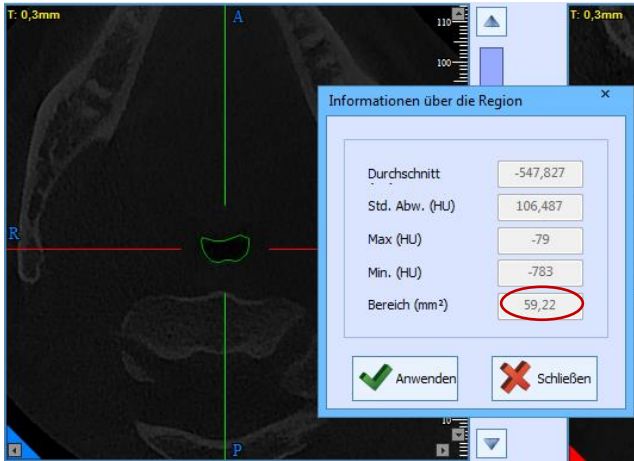
Nachher



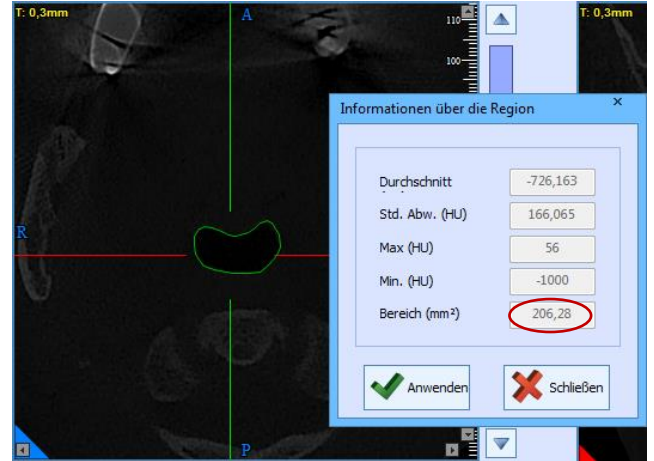
Maric, Ivan

AHI PräOP: 17,2/h am 20.02.16 | AHI PostOP: 1,7/h am 12.02.18

Vergleich der Fläche (Engste Stelle Vorher-Nachher)



Vorher



Nachher

